

Improved Healing of Stage 3 Pressure Ulcers Using Extracellular Matrix Collagen Dressings.

• Gregory Bohn, MD, FACS, ABPM/UHM, CWSP, FACHM • Sue Champion RN, CWOCN
West Shore Center for Wound Care and Hyperbaric Medicine, Manistee, MI

Purpose:

A retrospective case review was conducted to evaluate the benefit of a combination wound dressing protocol for treating Stage 3 pressure ulcers that could be left on the wound for a week.

Introduction:

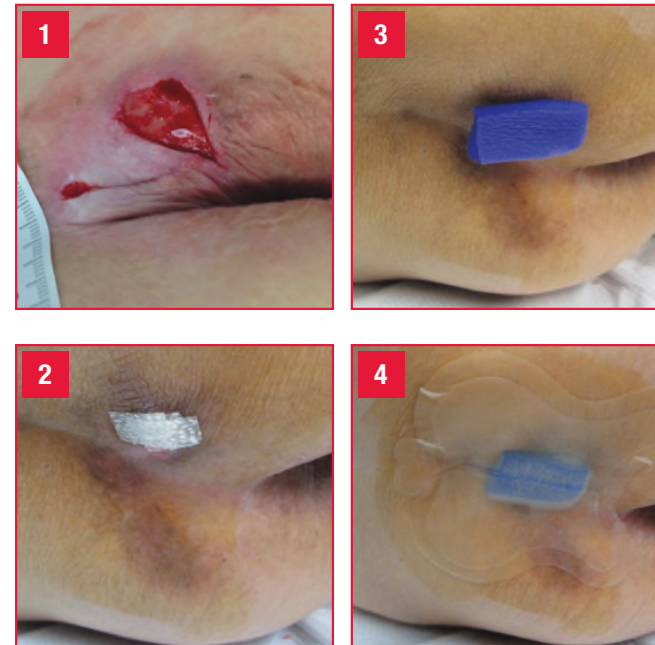
Stage 3 pressure ulcers are a major challenge for the clinician to heal. Using a combination dressing protocol may improve healing. Multiple randomized controlled trials have demonstrated the superiority of hydrocolloid dressings over plain gauze in the treatment of pressure ulcers.¹ One RCT including 65 residents with Stage 3 pressure ulcers in long term care facilities demonstrated similar healing rates of hydrocolloid dressings vs standard collagen dressings.³ The benefits of collagen to modulate excess matrix metalloproteinase (MMP) activity in a wound have been documented. A low MMP level is conducive to healing rather than a high level which can delay or retard healing.² When treated in the outpatient setting, using a dressing that would be effective for the weekly episode of care would be ideal. A combination dressing protocol was developed and evaluated for the treatment of Stage 3 pressure ulcers.

Methodology:

A retrospective case review of 17 patients with Stage 3 pressure ulcers from long term care facilities patients were followed on a weekly basis at the wound care center. Initial excisional debridement was performed in all cases followed by subsequent debridement as needed during the treatment phase. Pressure reduction with mattress overlays and or seat cushions were ordered as needed. As part of the overall wound care plan, the

combination dressing protocol developed consisted of a ovine collagen extracellular matrix dressing* (CECM) used as the primary dressing (Photo 2), a hydrogel (if needed for moisture balance), and methylene blue/gentian violet (MB/GV) polyurethane (PU) antibacterial foam** (Photo 3) for management of bio burden, which was held in place with a generic hydrocolloid cover dressing (Photo 4). Dressing changes were performed weekly. Peri-wound skin was prepped with tincture of benzoin swabs to improve adherence of the hydrocolloid cover dressing. If the dressing dislodged before the next weekly clinic visit, care givers

Combination Dressing Protocol

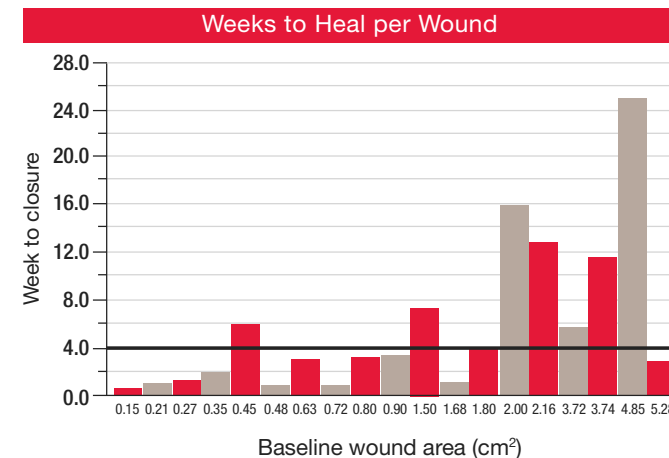


were instructed to reapply the collagen and foam portion of the dressing with a hydrocolloid cover. Wound assessment, simple wound measurements, and wound photographs were obtained at each weekly patient visit.

Results:

N patients	17
N wounds	21
Gender	7 males, 10 females
Age (mean, range)	75 years (41 – 93)
BMI (mean, range)	29.1 (13.6 – 64.2)
Braden Scale (mean, range)	15.2 (11 – 17)
Baseline Wound Area (mean, range)	1.62 cm ² (0.15 – 5.28)

Seventeen patients presented with 21 Stage 3 sacrococcygeal area pressure ulcers. Nineteen wounds were followed to closure. Twelve of nineteen (12/19), 63.2% of the wounds healed in 4 weeks or less. All 19 wounds healed in a mean



of 5.6 weeks (range .9-25.1 weeks). Median time to healing was 2.9 weeks. Two patients did not complete the study: One patient moved out of the area, but the wound volume reduced 71% in 6.6 weeks and the other patient deceased with the wound volume reduced 67% at 1 week.

Discussion:

In a comparative randomized controlled trial of 65 residents of skilled nursing home facilities with pressure ulcers, 13 patients had Stage 3 pressure ulcers.³ Either a collagen dressing or a hydrocolloid dressing were used to treat the wounds. When a collagen or hydrocolloid dressing were used alone, healing at 4 weeks did not occur.

In this retrospective case review, it appeared that using this combination dressing protocol with the CECM collagen dressing used in conjunction with MB/GV PU antibacterial foam and a hydrocolloid, complete healing was observed in 12 of 19 (63.2%) of stage 3 pressure ulcers at 4 weeks.

Conclusion:

Given that wound closure occurred in the majority of these Stage 3 pressure ulcers within 4 weeks, in this retrospective case review it appears to suggest that this dressing protocol did show effective wound closure on a timely basis.

REFERENCES

- Zheng, Xuemei, and Jieqiong Li. "Comparison of the Treatment of Hydrocolloid and Saline Gauze for Pressure Ulcer: A Meta-Analysis of Randomized Controlled Trials." *International Journal of Clinical and Experimental Medicine* 8.11 (2015): 20869–20875. Print.
- Muller, M et al. "Matrix Metalloproteinases and Diabetic Foot Ulcers: The Ratio of MMP-1 to TIMP-1 is a Predictor of Wound Healing." *Diabetic Medicine* 25.4 (2008): 419–426. PMC. Web. 29 Sept. 2016.
- Graumlich JF, et al; Healing Pressure Ulcers with Collagen or Hydrocolloid: A Randomized Controlled Trial. *JAGS* 2003. 51:147-154.

* Endoform dermal template, Distributed by Hollister Incorporated.
** Hydrofera Blue Ready foam, Distributed by Hollister Incorporated.

Financial Disclosure: The author received an honorarium from Hollister Incorporated.