

Multi-Center Evaluation of an Advanced Extracellular Matrix Technology for the Management of Chronic Wounds – A Canadian Experience



¹Rose Raizman, RN-EC, PHCNP, NSWOC, WOCC (C), MSc, MScN; ²Rosemary Hill, RN, BSN, CWOCN and ³Kevin Woo, PhD, RN, NSWOC, WOCC(C), FAPWCA
¹Lawrence S. Bloomberg Faculty of Nursing, University of Toronto Scarborough Health Network|Centenary Hospital, Toronto; ²Vancouver Coastal Health – Lions Gate Hospital;
³Queen's University, West Park Health Center, Toronto Western Hospital

Introduction

ECM^ϕ technology works as a scaffold to help rebuild missing or damaged tissue. Unlike traditional collagen dressings, ECM^ϕ is entirely natural, and is an accurate mimic of the scaffold found in healthy tissue. ECM^ϕ contains collagen, but also a range of other secondary molecules that are important for healing¹. Additionally, ECM^ϕ has been shown to modulate wound proteases². The aim of this case series was to clinically evaluate an advanced extracellular matrix (ECM^ϕ) technology across different Canadian care settings for the management of chronic wounds.

Methods

Thirty patients were recruited from three sites (see also population summary below). Wound types included DFU's, PU's, skin tears, pilonidal sinus, necrotizing fasciitis, venous leg ulcers, dehisced abdominal and traumatic wound. Wound management was undertaken across various care settings, including in-patient, out-patient and home health. All wounds were managed with best practice, including debridement, maintenance of a moist wound environment and appropriate compression and off-loading. All wounds were managed with an ECM^ϕ, applied every 2-7 days to the wound bed. Wounds were visually inspected, imaged and measured over the course of management with ECM^ϕ.

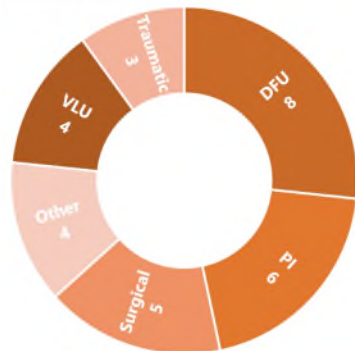
Population

Demographics and Wound Types

30
Wounds

19
(63%)

11
(37%)



Average wound age:
23 weeks

Range 0 to 104 weeks

Baseline average wound size:
23 cm²

Range 0.1 to 165 cm²

Results

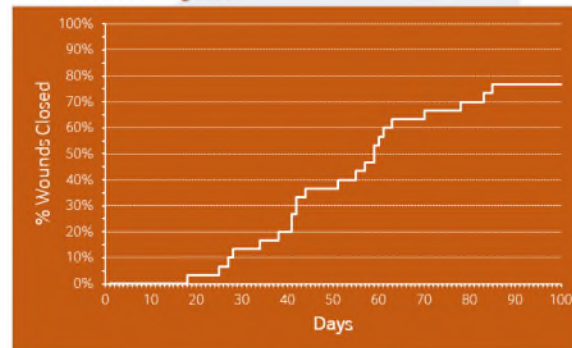
Outcomes

Wounds closed:
77%
(By week 12;
n=23/30)

Average % wound size
at 4 weeks:
36%
(SD=33%; range, 0%
to 96%)

'Respondents' at 4 weeks:
70%
(>50% reduction in area
at 4 weeks; n=21/30)

Survival Analysis:



'Respondents' sub-analysis:

VLU:	50% (n=2/4)	Surgical:	100% (n=5/5)
DFU:	75% (n=6/8)	Traumatic:	67% (n=2/3)
PI:	67% (n=4/6)	Other:	50% (n=2/4)

Conclusions

This represents the first Canadian evaluation of ECM^ϕ for the management of wounds. Improvements to the granulation tissue were observed, and otherwise stalled chronic wounds began to resolve^{3,4}. Results to date are encouraging, and the availability of this advanced technology to Canadian wound specialists provides another tool for the management of these complex pathologies.

References and Disclosures

- Lun, S., et al., A functional extracellular matrix biomaterial derived from ovine forestomach. *Biomaterials*, 2010. **31**(16): p. 4517-29.
- Negroni, L., S. Lun, and B.C.H. May, Ovine forestomach matrix biomaterial is a broad spectrum inhibitor of matrix metalloproteinases and neutrophil elastase. *Int Wound J*, 2014. **11**(4): p. 392-397.
- Bohn, G.A., et al., Proactive and Early Aggressive Wound Management: A Shift in Strategy Developed by a Consensus Panel Examining the Current Science, Prevention, and Management of Acute and Chronic Wounds. *Wounds*, 2017. **29**(11): p. S37-S42.
- Bohn, G.A. and K. Gass, Leg ulcer treatment outcomes with new ovine collagen extracellular matrix dressing: a retrospective case series. *Adv Skin Wound Care*, 2014. **27**(10): p. 448-54.

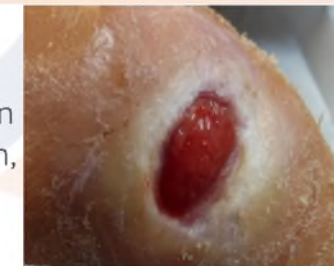Financial support was provided by Aroa Biosurgery Limited (New Zealand). The authors would like to acknowledge the assistance of Drs. Vonne Heeswijk and Sandi Dempsey in data analysis and preparation of this poster.

*Endoform Natural Dermal Template; †Hydrofera Blue Classic; www.appulsemed.com

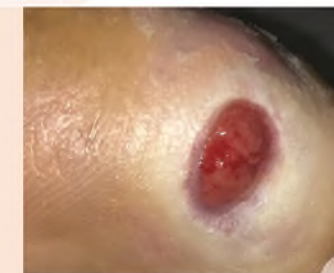Case Study 1

Patient: 60 year old male.
Medical History: Non-insulin-dependent diabetic (Hgb A1c 7.2%), original transtetatarsal amputation in 2016.
Wound Description: Diabetic foot ulcer, painful when infected otherwise has neuropathy to plantar aspect of his foot.
Previous Treatments: Two courses of antibiotics, gauze dressing.

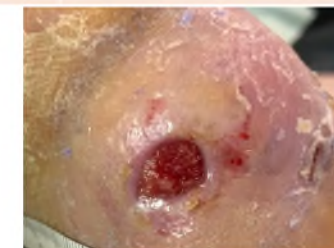Week 0:
2.0 x 1.2 cm.
100% granulation tissue, maceration, neuropathy.
ECM^ϕ, GV/MB* foam.



Week 1:
1.0 x 0.9 cm.
100% pink granulation tissue, moisture.
ECM^ϕ, GV/MB* foam, TCC.



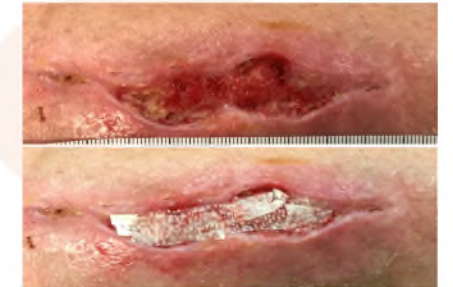Week 5:
0.8 x 0.5 cm.
83% wound closure.



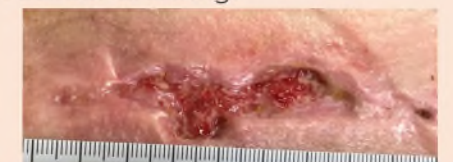Case Study 2

Patient: 54 year old female.
Medical History: Celiac disease, hypertension, idiopathic neutropenia.
Wound Description: Post surgical wound.
Previous Treatments: Dressings, topical antibiotic, debridement, cadexomer iodine.

Week 0:
5.8 x 2.0 cm. 10% slough, 90% granulation tissue. ECM^ϕ, GV/MB* foam border dressing, light compression sock.



Week 2:
3.8 x 1.7 cm. Epithelialization, 100% granulation tissue. ECM^ϕ, GV/MB* foam border dressing.



Week 5:
Wound closed.

