

# The use of an ovine collagen extracellular matrix dressing in conjunction with negative pressure wound therapy in the management of chronic diabetic foot ulcers.

• Gregory Vidovic, DPM, Resident • Paul Sykes, DPM, Director  
University General Hospital Podiatric Surgery Residency, Houston, TX

## Introduction:

The use of negative pressure wound therapy dressings (NPWT) on acute and chronic foot wounds is not only well established, it has become a modern paradigm in the treatment of difficult-to-treat, pervasive wounds. The role of NPWT in promoting healing is based on a compendium of effects included induction of granulation tissue, removal of exudates, decreasing bioburden and maintaining a hydrated healing environment.<sup>5,6</sup> Additionally, the application of a collagen dressing over chronic wounds has shown an overall decrease in wound surface in a case series of diabetic foot ulcers.<sup>6</sup> A class of several zinc-containing serine proteases including interstitial collagenases, gelatinases, and stromelysins collectively are known as the matrix metalloproteinases (MMPs). MMP levels have been shown to be markedly elevated in chronic wounds among a plethora of other pathologic conditions. Here we present ten cases where NPWT was combined in conjunction with ovine collagen extracellular matrix dressing (CECM)\* with an overall difference in time to wound closure compared to a retrospective control group in which this dual therapy was not used.

## Materials and Methods:


A prospective case-control study was initiated after approval from the institutional review board. Patient selection and enrollment was non-randomized and continuous until the treatment group of ten patients was filled, with cases of NPWT paired with CECM. The control group data was constructed utilizing a retrospective analysis of the last ten patients previously treated with NPWT alone. The goal of the study was to evaluate and compare the overall time to wound closure of both groups.

## Results:

The results demonstrated in chronic diabetic foot ulceration an average time to closure of 5.5 weeks in the treatment group using the CECM dressing and 7 weeks in the control group. This shows a mean difference of 10 days in time to wound closure when CECM as added to the regimen with NPWT. There were no adverse events reported.

## Conclusion:

In this case series, when compared to NPWT alone, the addition of CECM to NPWT has shown a difference in time to wound closure in instances of long-standing diabetic foot ulcers.



REFERENCES  
 1. American Diabetes Association. Standards of Medical Care in Diabetes - 2015. Diabetes Care, 38 (suppl 1): S1-S2, doi: 10.2337/7015-0001  
 2. Leaper D, Assadian O, Edmiston CE. Approach to Chronic Wound Infections. Br J Dermatol. 2015; Epub Mar 15. doi: 10.1111/bjd.13677  
 3. Imraskolgu C, Sethi S, Schneider C, Hain T, Chakraborty T, Maysner P, Domann E. Distinct polymicrobial populations in a chronic foot ulcer with implications for diagnostic and anti-infective therapy. BMC Res Notes. 2014; Mar 29;7:196. doi: 10.1186/1756-0500-7-196  
 4. O'Meara S, Al-Kurdi O, Duggan Y, Dvingin LG, Moryn S, James M, Richardson R. Antibiotics and antiseptics for venous leg ulcers. Cochrane Database Syst Rev. 2013 Dec 23; 12:CD005557. Epub 2013 Dec 23.  
 5. Hasan MY, Teo R, Nather A. Negative-pressure wound therapy for management of diabetic foot wounds: a review of the mechanism of action, clinical applications, and recent developments. Diabetic Foot Ankle. 2015 Jul 1;8:27616.  
 6. Haycock S, Chadwick P, Cutting KF. Collagen matrix wound dressings and the treatment of DFUs. J Wound Care. 2013 Jul;22(7):369-70, 372-5.  
 \* Endoform dermal template. Distributed by Hollister Incorporated.

## Case Study 1

Diabetic foot 3 weeks status post debridement for infection of left foot

### Past medical history:

- Diabetes mellitus, hypertension, obesity, chronic kidney disease-Stage 3

### Wound history:

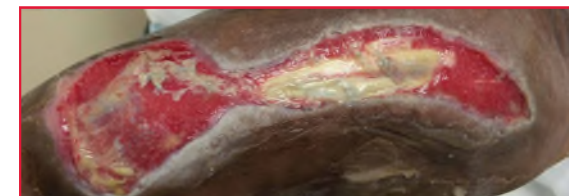- 3 weeks status post excisional debridement of infected dorsal medial foot wound that began as hallux ulceration and tunneled into the medial mid-foot along the first ray

### Previous treatment:

- Sharp debridement, wet to dry dressings, double antibiotic ointment, hydrogel, silver alginate dressing

### Current treatment:

- Weekly debridement with application of CECM and NPWT



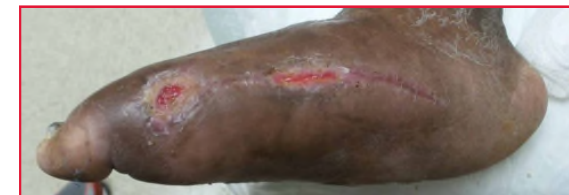Week 0



Application of CECM dressing



Application of NPWT over CECM



Week 6

## Case Study 2

Right diabetic foot ulcer

### Past medical history:

- Diabetes mellitus, hypertension, obesity, hypothyroidism, fibromyalgia, Charcot neuroarthropathy

### Wound history:

- 3 month history of chronic, recurrent plantar ulcer at greater tarsus fault secondary to Charcot collapse

### Previous treatment:

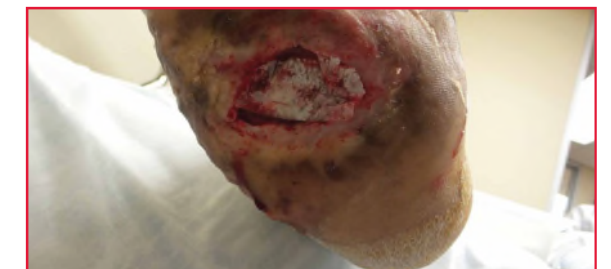- Curettage, wet to dry dressing, silver foam dressing, medical grade honey products, and off-loading boot

### Current treatment:

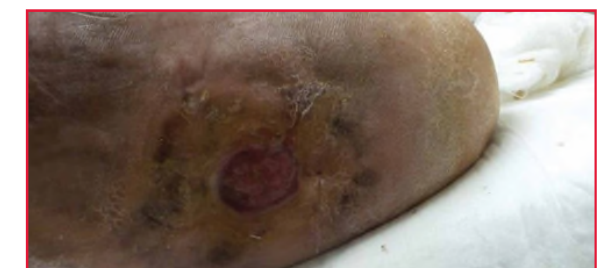- Weekly debridement with application of CECM and NPWT



Week 0



Application of CECM prior to NPWT



Week 7