

# Pressure Injury Reconstruction Utilizing an Ovine Forestomach Matrix Graft

Abigail E. Chaffin<sup>1</sup>, MD, FACS, CWSP, FAPWCA & Michael N. Desvigne<sup>2</sup>, MD, FACS, CWS, FACCWS

<sup>1</sup>Chief – Division of Plastic Surgery, Tulane University, New Orleans, LA, USA; <sup>2</sup>Department of Plastic Surgery, Abrazo Arrowhead Hospital, Glendale, AZ, USA

## INTRODUCTION

The burden of pressure injuries (PI) remains a substantial problem with over 1 in 10 adults patients admitted to hospitals affected with PIs [1]. As of 2011 it was estimated that the cost of treating a stage 4 PI and its related complications was \$129,248. Additionally, the average 6 month post operative healing rate for a stage 4 PI is 31-34% and the post operative complication rate after flap reconstruction is reported to be 58.7%. Herein we present the use of an ovine forestomach matrix (OFM) graft in PI reconstruction. OFM is an intact extracellular matrix graft that has demonstrated an ability to modulate tissue proteases [3], promote angiogenesis [4] and is resilient in contaminated wounds [5-7]. The authors hypothesize that the addition of OFM would decrease post-operative complications and healing times seen in PI reconstruction.

## METHODS

This is a multicenter retrospective case series analyzing 9 cases (n=9) in which OFM was utilized as part of PI reconstruction. Patients were followed up with after application and until wound closure or a healed surgical incision.

## RESULTS

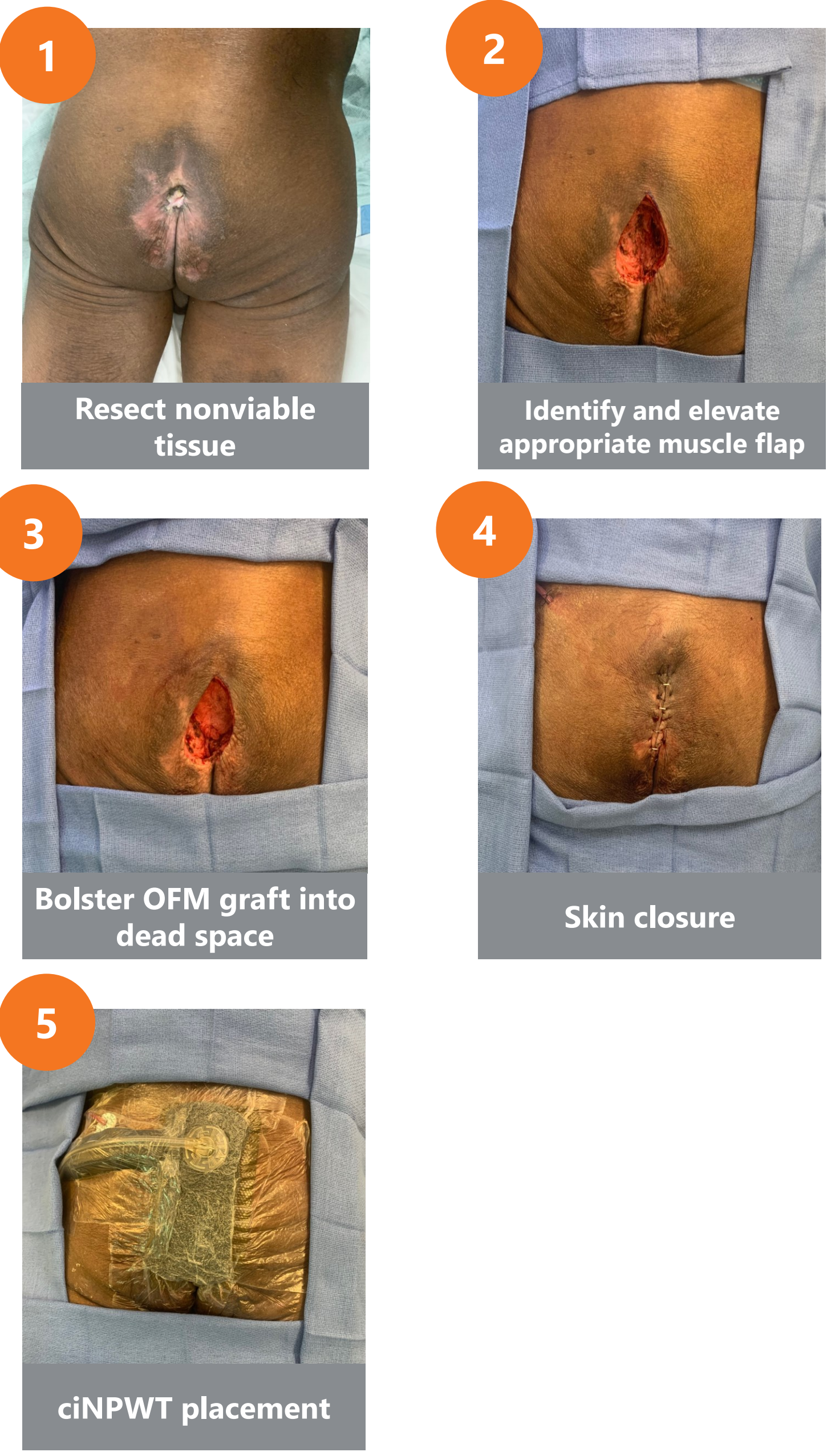
All patients presented with a Stage 4 PI and there were 6 males and 3 females. All patients underwent a flap surgical reconstruction with the use of OFM as an implant. All nine flap reconstruction patients had healed surgical incisions with no significant post operative complications. There was one mild post operative dehiscence that healed by 3 months and remained healed at 6 months.

## CONCLUSION

OFM may assist in the accelerated healing of PIs and lower the complication rate with flap closure. Further studies are needed to expand on this pilot experience of adding OFM to the reconstruction of PIs.

Sex/Age	Comorbidities	History	Defect Measurement	Outcomes
M, 51	Paraplegic	<ul style="list-style-type: none"> <li>Presented with recurrence of left ischial and trochanteric PI</li> <li>Previously had gluteal flap for sacral ulcer, VY hamstring flap for left ischial ulcer</li> <li>Patient lost power from hurricane and the electric offloading bed and wheelchair failed.</li> <li>Resulted in Stage 4 ischial and trochanteric PI with underlying osteomyelitis</li> </ul>	~20 x 30 cm	<ul style="list-style-type: none"> <li>Fully healed at 6 weeks</li> <li>No recurrence, last follow-up week 18</li> <li>No complications</li> </ul>
M, 66	ESRD	<ul style="list-style-type: none"> <li>Presented with stage IV sacral decubitus pressure injury after prolonged ICU stay for gallstone pancreatitis</li> </ul>	~10 x 10 x 5 cm	<ul style="list-style-type: none"> <li>Fully healed at 5 weeks</li> <li>No recurrence at week 18</li> <li>No complications</li> </ul>
M, 24	Paraplegic after GSW	<ul style="list-style-type: none"> <li>Presented with stage IV bilateral ischial pressure injury.</li> <li>Previous history of E. coli and Strep infections with underlying ischial tuberosity osteomyelitis suspected on MRI.</li> </ul>	~8 x 9 x 5 cm (bilateral)	<ul style="list-style-type: none"> <li>Fully healed at 5 weeks</li> <li>Drain pulled out accidentally week 1; small seroma left side</li> <li>No recurrence, last follow-up week 16</li> <li>No complications</li> </ul>
F, 49	Obesity	<ul style="list-style-type: none"> <li>History of COVID resulting in prolonged ICU stay in 2021</li> <li>Developed stage IV sacral PI from ICU stay, underwent debridements and wound care for 1 year with no significant progress</li> <li>MRI demonstrated concerning sign of osteomyelitis in the coccygeal and distal sacrum</li> </ul>	~8 x 7 x 7 cm	<ul style="list-style-type: none"> <li>Fully healed at 5 weeks</li> <li>Remained healed at 16 months</li> <li>No complications</li> </ul>
M, 25	Paraplegic after MVA	<ul style="list-style-type: none"> <li>Presented with a recurrent stage IV sacral decubitus pressure injury and a new stage IV left ischial pressure injury with significant osteomyelitis extending from ischium to posterior column of the acetabulum</li> <li>Patient has had previous V-Y advancement flap 3 years prior to sacral PI</li> </ul>	~15 x 15 x 8 cm	<ul style="list-style-type: none"> <li>Fully healed at 5 weeks</li> <li>No recurrence, last follow-up week 8</li> <li>No complications</li> </ul>
M, 56	DM Previous smoker	<ul style="list-style-type: none"> <li>Burned bilateral buttocks and thighs in 2017 in a roofing accident</li> <li>STSG failed leading to stage IV PI</li> <li>Initial attempt at reconstruction at outside center dehisced and now has recurrent stage IV PI with osteomyelitis of ischium</li> </ul>	~15 x 10 x 6 cm	<ul style="list-style-type: none"> <li>Fully healed at 4 weeks</li> <li>No recurrence, last follow-up week 6</li> <li>No complications</li> </ul>
F, 70	Paraplegic Multiple Sclerosis	<ul style="list-style-type: none"> <li>Presented with stage IV sacral pressure injury persisting for 6 months</li> <li>Previously treated with saline-moistened gauze and NPWT</li> </ul>	~15 x 6 cm	<ul style="list-style-type: none"> <li>Fully healed incision site</li> <li>Remained healed at 6 months</li> </ul>
F, 73	Parkinson's Disease Lupus Rheumatoid Arthritis	<ul style="list-style-type: none"> <li>Presented with stage IV sacral pressure injury persisting for 7 years</li> <li>Failed previous flap reconstruction</li> </ul>	~8 x 4 cm	<ul style="list-style-type: none"> <li>Mild postoperative dehiscence</li> <li>Secondary healing at 3 months</li> <li>Remained healed at 6 months</li> </ul>
M, 62	Parkinson's Disease Lupus Rheumatoid Arthritis Diabetes Mellitus Paraplegic	<ul style="list-style-type: none"> <li>Presented with stage IV sacral pressure injury persisting for 7 years, previously treated with calcium alginate</li> <li>No acute infection – though noted contamination and chronic inflammation noted</li> </ul>	<ul style="list-style-type: none"> <li>~8 x 4 cm (sacral)</li> <li>~7 x 7 cm (left ischial)</li> <li>~8 x 5 cm (right ischial)</li> </ul>	<ul style="list-style-type: none"> <li>Fully healed incision site</li> <li>Remained healed at 6 months</li> </ul>

## Surgical Algorithm



## REFERENCES AND DISCLOSURES

AEC and MND have received educational grants from Aroa Biosurgery, LTD  
 [1] Li, Z., F. Lin, L. Thalib and W. Chaboyer (2020). "Global prevalence and incidence of pressure injuries in hospitalised adult patients: A systematic review and meta-analysis." *Int J Nurs Stud* 105: 103546. [2] Bamba, R., J. J. Madden, A. N. Hoffman, J. S. Kim, W. P. Thayer, L. B. Nanney and M. E. Spear (2017). "Flap Reconstruction for Pressure Ulcers: An Outcomes Analysis." *Plast Reconstr Surg Glob Open* 5(1): e1187. [3] Negron, L., S. Lun and B. C. H. May (2012). "Ovine forestomach matrix biomaterial is a broad spectrum inhibitor of matrix metalloproteinases and neutrophil elastase." *Int Wound J* 11(4): 392-397 [4] Irvine, S. M., J. Cayzer, E. M. Todd, S. Lun, E. W. Floden, L. Negron, S. G. Dempsey, A. Alexander, S. P. Gunningham, C. Knight, P. F. Davis, B. R. Ward and B. C. H. May (2011). "Ovine Forestomach Matrix (OFM) Stimulates Angiogenesis In Vitro and In Vivo. SAWC, Dallas, Texas, USA. [5] Chaffin, A. E. and M. C. Buckley (2020). "Extracellular matrix graft for the surgical management of Hurley stage III hidradenitis suppurativa: a pilot case series." *J Wound Care* 29(11): 624-630. [6] Chaffin, A. E., S. G. Dowling, M. S. Kosyk and B. A. Bosque (2021). "Surgical reconstruction of pilonidal sinus disease with concomitant extracellular matrix graft placement: a case series." *J Wound Care*. [7] Desvigne, M. N., K. Bauer, K. Holifield, K. Day, D. Gilmore and A. L. Wardman (2020). "Case Report: Surgical Closure of Chronic Soft Tissue Defects Using Extracellular Matrix Graft Augmented Tissue Flaps." *Frontiers in Surgery* 7(173).