

# Clinical Effectiveness of Ovine Forestomach Matrix Graft in Complex Lower Limb Reconstruction and Limb Salvage

<sup>1</sup>M. Mark Melin (MD, FACS, RPVI, FACCWS); <sup>2</sup>Richard Kaufman (DPM, CWSP); <sup>3</sup>James E. Geiger, Jr. (DPM, CWSP); <sup>4</sup>Igor Zilberman (DPM); <sup>5</sup>Nooshin Zolfaghari (DPM, CWSP); <sup>6</sup>Howie Que (DPM); <sup>7</sup>James Longobardi (DPM); <sup>8</sup>William Dutch, Jr (DPM); <sup>9</sup>Joseph Skurka (DPM); <sup>10</sup>Brandon Bosque (DPM, CWSP); <sup>11</sup>Shane Dowling (MS-PAS, CWS)  
<sup>1</sup>M Health - Fairview, Edina, MN, USA; <sup>2</sup>Piedmont Atlanta Hospital, Atlanta, GA, USA; <sup>3</sup>Northwestern Medicine - Palos Health, Palos Heights, IL; <sup>4</sup>South Florida Lower Extremity Center, Davie, FL, USA; <sup>5</sup>Sharp Chula Vista Medical Center, San Diego, CA, USA; <sup>6</sup>CNY Foot Surgery, East Syracuse, NY, USA; <sup>7</sup>Ephraim McDowell Regional Medical Center, Danville, KY, USA; <sup>8</sup>Aroa Biosurgery Limited, Auckland, New Zealand

## INTRODUCTION

Chronic lower extremity defects may lead to major amputations and have severe consequences on patient quality of life, and ultimately, mortality[1]. There are several pathways to surgical closure of these defects with robust coverage of any exposed vital structures (i.e. bone, tendon, arteries) or volumetric fill often being the initial goal. Ovine forestomach matrix scaffold (OFM) technology has been developed as a robust planar sheet or particulate form which can be utilized in volumetric, contaminated wounds to rapidly build tissue and provide cover to exposed structures with viable granulation, ultimately shortening the time to definitive closure. The OFM graft format is indicated for dermal regeneration and implant procedures.

## METHODS

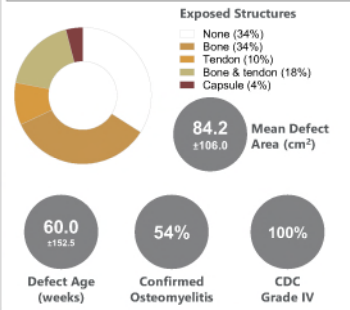
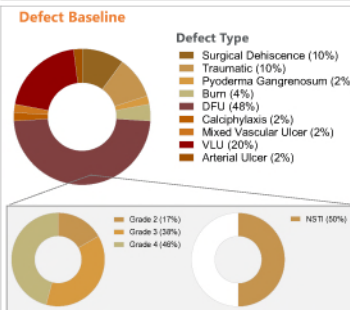
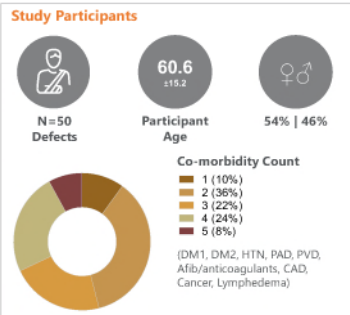
A total of 50 case records were evaluated (n=50) across seven (7) healthcare centers across the United States. Case records were reviewed to identify: patient comorbidities, defect etiology (e.g. NSTI, DFU, burn, etc.), defect size, presence of exposed structures, CDC contamination score, Wagner score, OFM graft usage, time to 100% granulation tissue, STSG usage, overall time to heal and any post-operative complications. Patient demographics, baseline wound characteristics and healing outcomes were analyzed with descriptive statistics.

## CONCLUSION

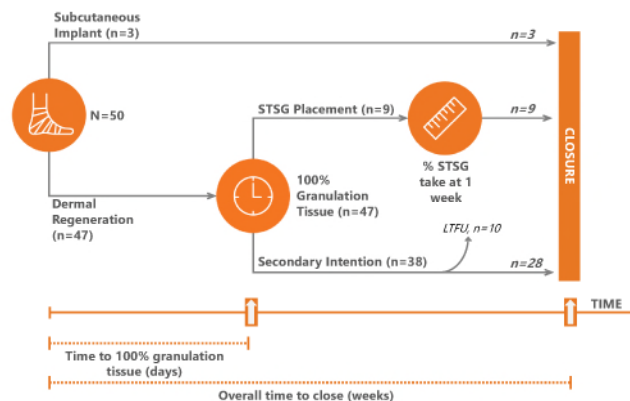
This IRB-approved retrospective case series demonstrates OFM as a clinically effective treatment modality in the surgical management of complex lower extremity soft tissue defects with exposed structures and multi-morbid patients. A single application of the graft was effective in regenerating well vascularized neodermis, often in the presence of exposed structures within 26.0±22.2 days, in a complex patient cohort who might otherwise have lost extremities to amputation[2]. These data support the use of OFM as a safe, cost-effective, and clinically effective treatment option to granulate over exposed vital structures and shorten time to definitive closure.

## REFERENCES AND DISCLOSURES

<sup>1</sup>Myriad Matrix™ and Myriad Morcells™ (Aroa Biosurgery Limited, New Zealand). [1] Meshkin DH, Zolper EG, Chang K, Bryant M, Bekeny JC, Evans KK, Attinger CE, Fan KL. Long-term Mortality After Nontraumatic Major Lower Extremity Amputation: A Systematic Review and Meta-analysis. J Foot Ankle Surg. 2021 May; Jun50(3):567-576. [2] Flood, M. S., B. Weeks, K. O. Anaeme, H. Aguirre, K. B. Hobitzel, S. E. Jiongco, R. J. Klein, A. Lemoi, R. Rafofs and A. S. Landsman (2020). "Treatment of Deep Full-thickness Wounds Containing Exposed Muscle, Tendon, and/or Bone Using a Bioactive Human Skin Allograft: A Large Cohort Case Series." Wounds 32(6): 164-173.



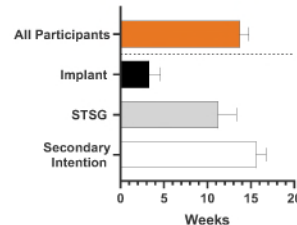
## Surgical Pathway and Study Measures



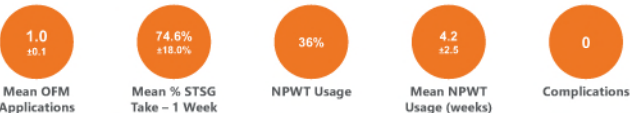## Study Outcomes

**26.0 ±22.2 Days**

**Mean Time to 100% Granulation Tissue**

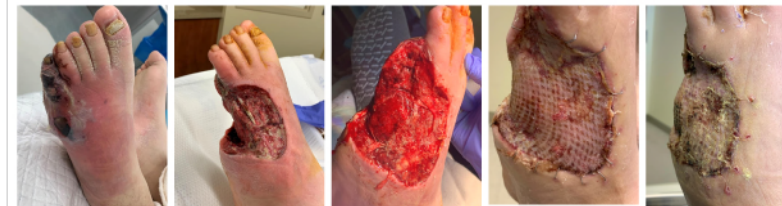

**Mean Overall Time to Close (weeks)**



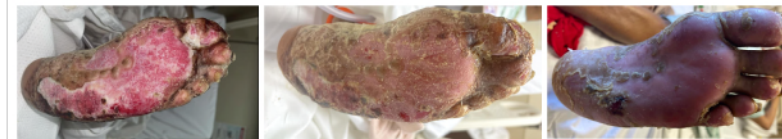## Example Case #1: Staged procedure with STSG. 28-year-old male diabetic - Wagner 4, necrotizing infection.

Week 0: Initial Presentation Week 0: Partial ray resection, exposed tendon and bone Week 1: 100% Granulation tissue - place STSG Week 3: 90% STSG take Week 5: Healed



## Example Case #2: Dermal regeneration. 39-year-old female diabetic - deep partial-thickness burn.

Week 0: Pre-operative presentation Week 2: Healed after one OFM application Week 12: Long-term follow-up, remains fully epithelialized



## Example Case #3: Dermal regeneration. 62-year-old female diabetic, PAD - Pyoderma Gangrenosum.

Week 0: Initial Presentation Week 0: Intra-operative application of OFM, covering exposed tendon Week 7: 100% granulation - coverage of exposed tendon, residual OFM noted Week 21: Application of STSG Week 26: Healed, no recurrence as of 5 months

