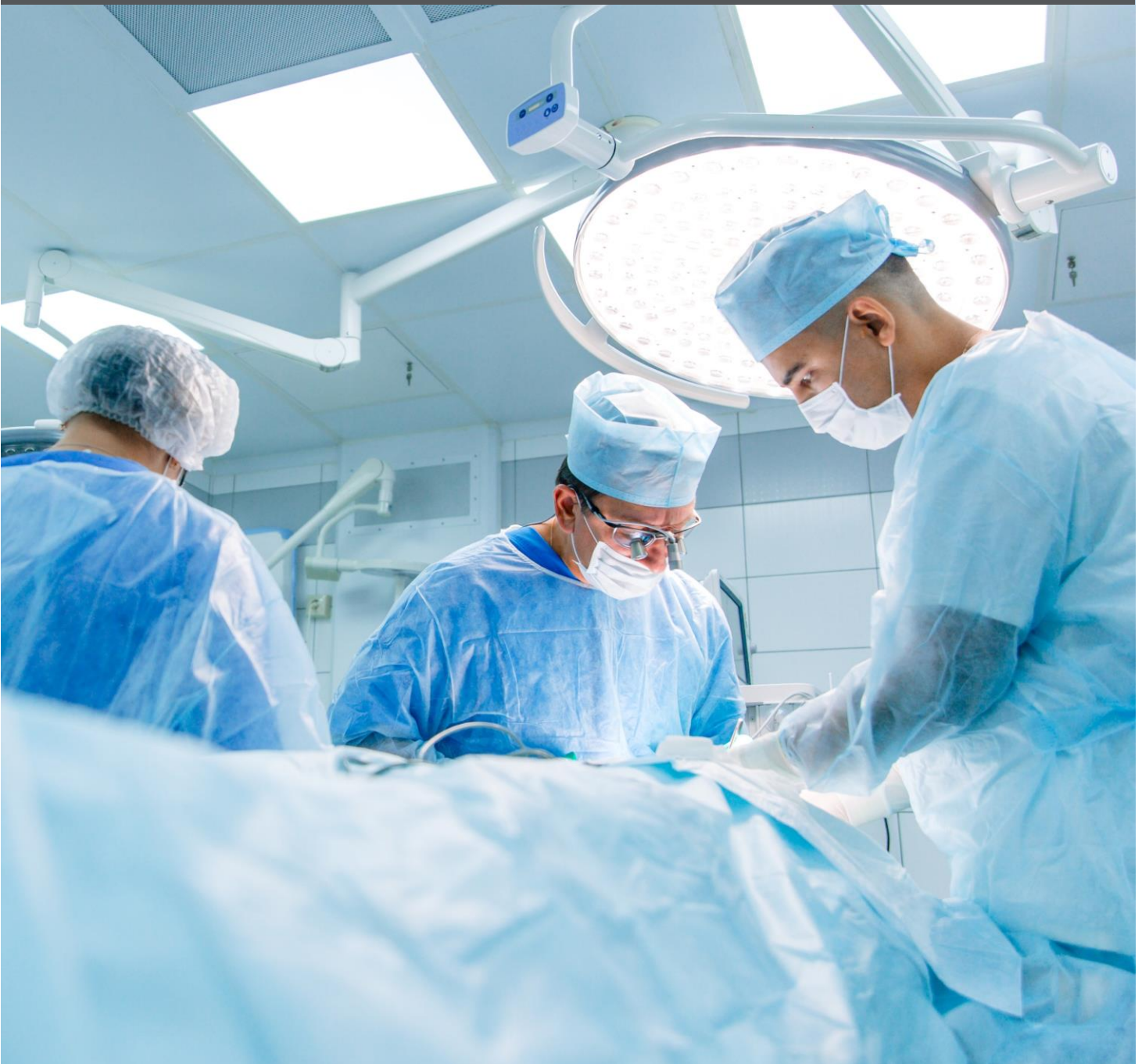



Hidradenitis Suppurativa

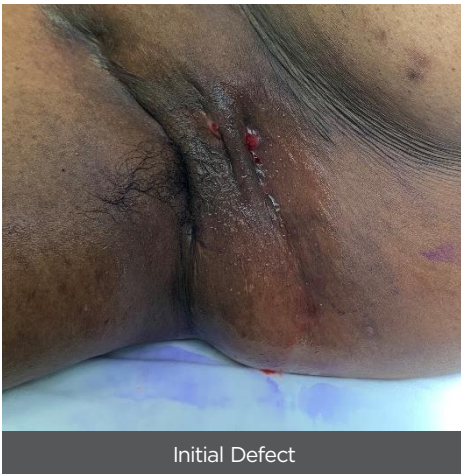Clinical Resource



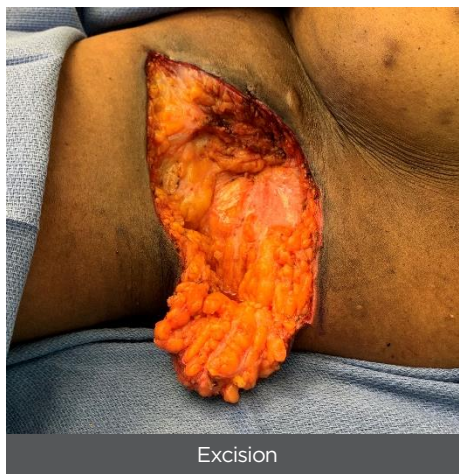
Hidradenitis Suppurativa Clinical Resource

Axilla Reconstruction

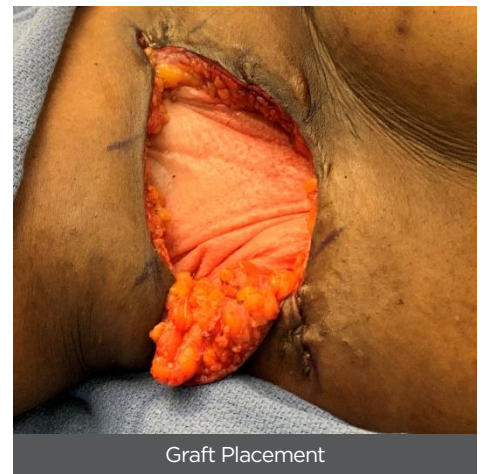
26-Year-old female. Five years of Hurley grade III Hidradenitis Suppurativa with multiple draining and interconnected sinuses. Previously managed with topical antibiotics and laser treatments. Full thickness excision of affected area (~20 x 10 x 4 cm). Myriad Matrix (5-layer, 10 x 20) placed in the defect prior to fasciocutaneous flap mobilization. Cover dressing lost at week 3 leading to minor dehiscence at the incision. Endoform Natural used from week 4 to epithelize the dehisced primary closure.¹



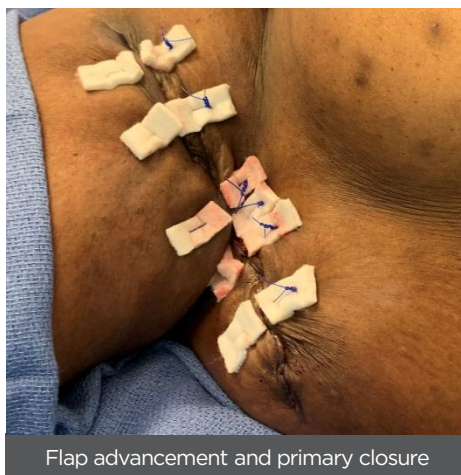
Initial Defect



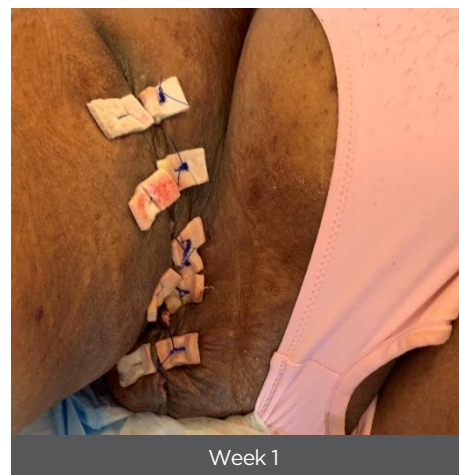
Excision



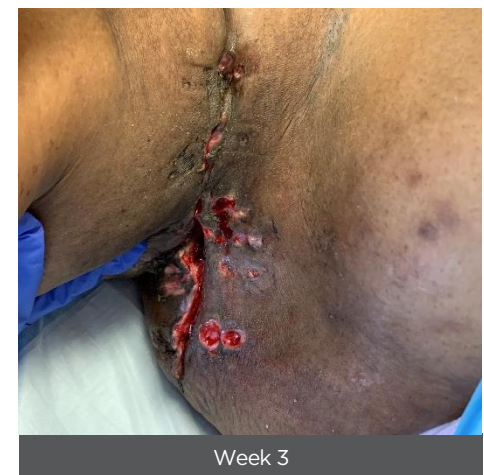Graft Placement



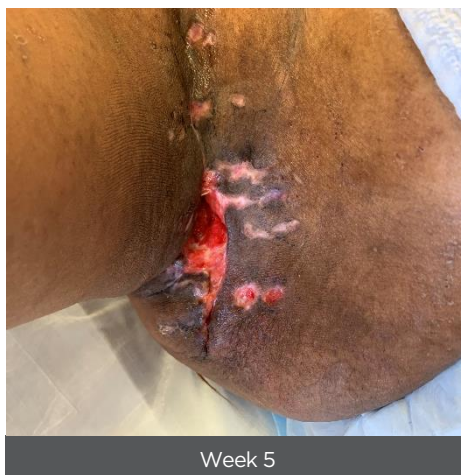Flap advancement and primary closure



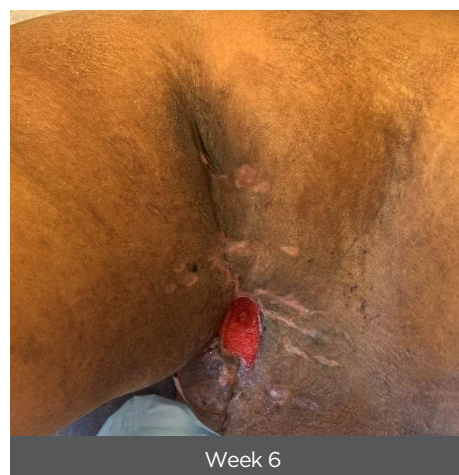
Week 1



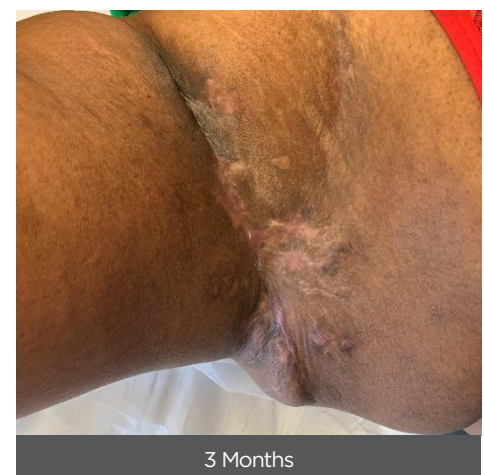
Week 3



Week 5



Week 6

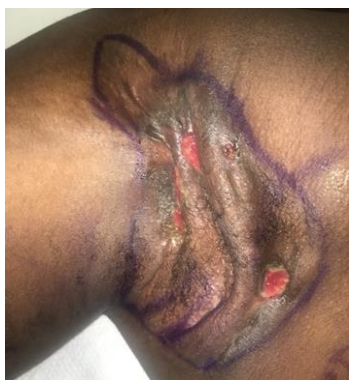

3 Months

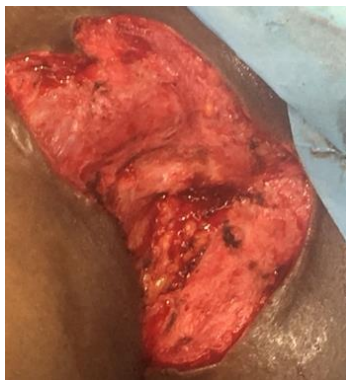Hidradenitis Suppurativa Clinical Resource

Axilla Reconstruction

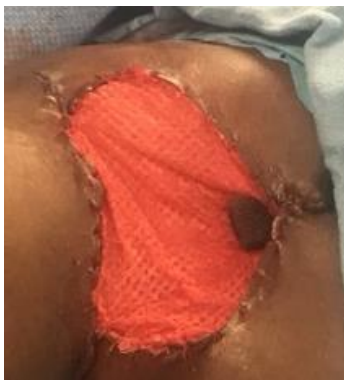29-Year-old male. Two years of Hidradenitis Suppurativa (Hurley grade III). Full thickness excision down to fascia (~12 x 7 x 1 cm). Myriad Matrix (5-layer, 10 x 20) sutured to the defect, then NPWT. Evidence of graft integration at Day 4. Debridement of surface layers at Day 10 revealed a well vascularized granulation bed. Defect epithelializing at week 4, and ~80% closed by week 8.¹



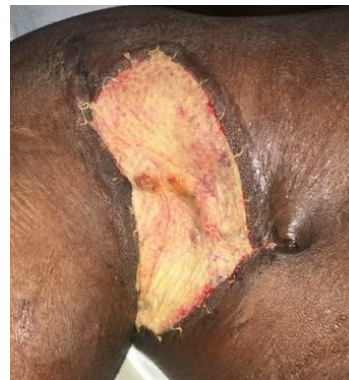Initial Defect



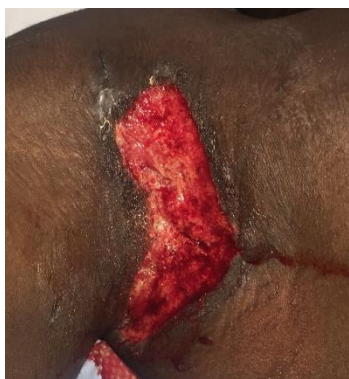Excision



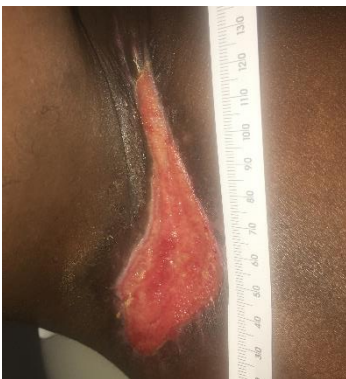Graft Placement



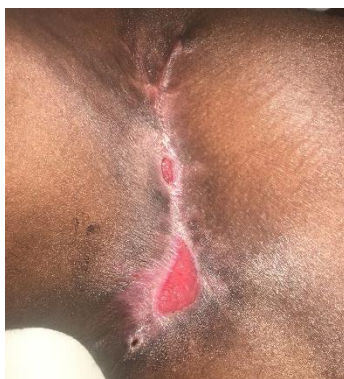Day 4



Day 10



Week 4



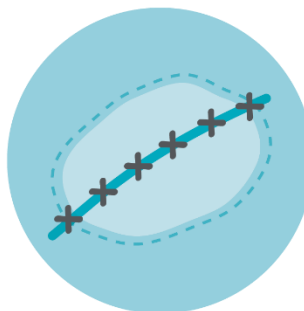
Week 8

Versatile


Engineered extracellular matrix for soft tissue repair, reinforcement and complex wounds.

Myriad Matrix™ is indicated for both implant and dermal procedures.

Implantation



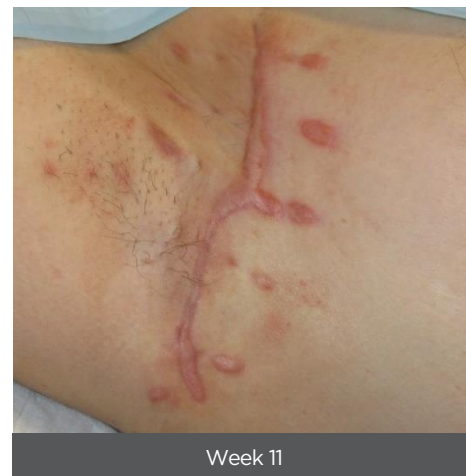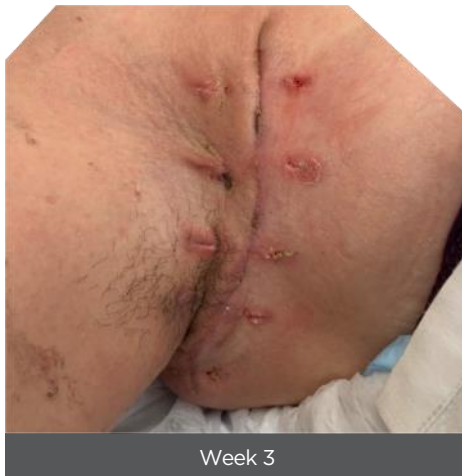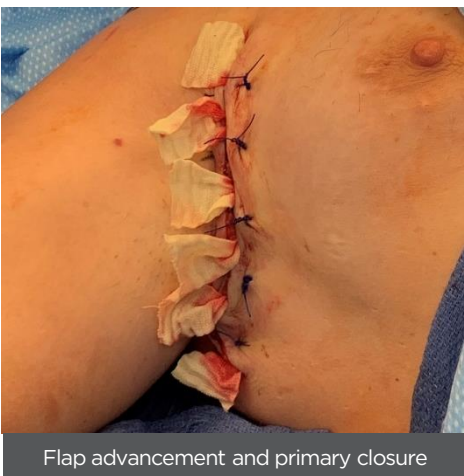
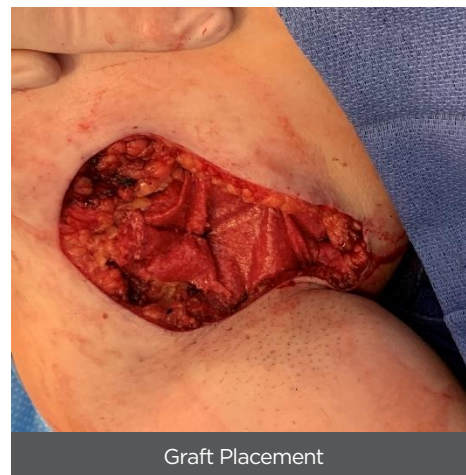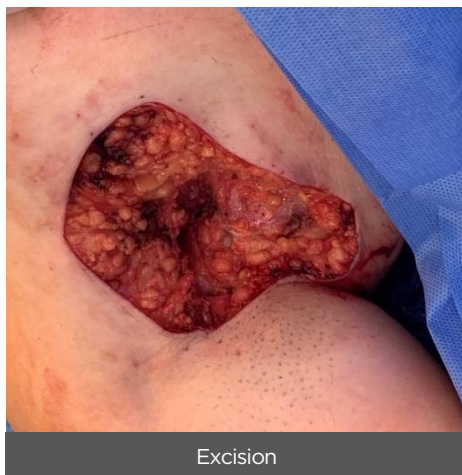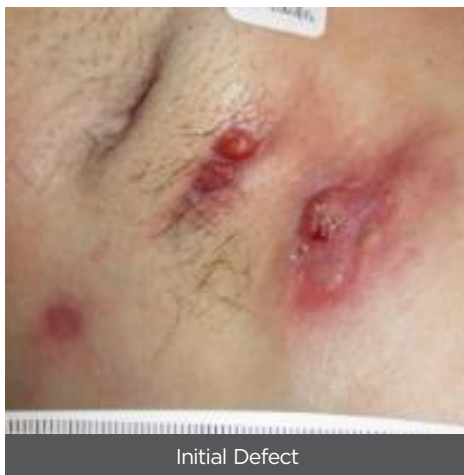Dermal Repair



Hidradenitis Suppurativa Clinical Resource

Axilla Reconstruction

5 Years of Hurley grade III Hidradenitis Suppurativa with multiple draining and interconnected sinuses. Full thickness excision (~15 x 15 cm) of affected area. Myriad Matrix (3-layer, 10 x 10 cm) placed in the defect prior to flap advancement. Healed at 3 weeks, no complications at 11 weeks.¹



References

1. Chaffin, A. E. and M. C. Buckley (2020). "Extracellular matrix graft for the surgical management of Hurley stage III hidradenitis suppurativa: a pilot case series." J Wound Care 29(11): 624-630.

Prior to use, be sure to read the entire Instructions For Use package insert supplied with the product.
Consult your local sales representative for country specific information.



AROA BIOSURGERY LTD
2 Kingsford Smith Place, Airport Oaks,
Auckland 2022, New Zealand
www.aroabio.com

AROA™, AROA ECM™, Myriad Matrix™ and Endoform™ are trademarks of Aroa Biosurgery Limited.

MKT.1551.02 | December 2021