

To Preserve and Protect: a Dual Approach to Wound Management using an Extracellular Matrix with Ionic Silver

James Stillerman, MD

Samaritan Wound Care Center, Watertown, NY

Introduction

Many factors can hinder the correct trajectory of wound healing. In this case series, challenging or at-risk injuries were managed with a dual approach to preserve the healing trajectory of the wound bed as well as protect from infection. Using an extracellular matrix embedded with ionic silver (ECM-Ag[®]).

Methods

In this case series, a range of wound types and injuries (n=7) were managed using a dual approach combining an advanced ECM with ionic silver. ECM-Ag devices were applied weekly, or as required, along with a GV/MB cover dressing[#]. Wound size, absorption of the ECM-Ag device, the development of granulation tissue and re-epithelialization of the wound bed, as well as the presence or absence of microbial colonization were assessed.

Conclusions

Based on the assessment criteria, ECM was incorporated into all wounds which developed granulation tissue and closed or were reduced in size, with no signs of infection after ECM-Ag application. The average reduction in wound size was 41% after 4 weeks. This combinatorial approach to preserve and protect difficult-to-heal wounds should be considered to promote a positive healing trajectory.

References and Disclosures

Financial support was provided by Aroa Biosurgery Limited (New Zealand)

[#]Endoform Antimicrobial Dermal Template;

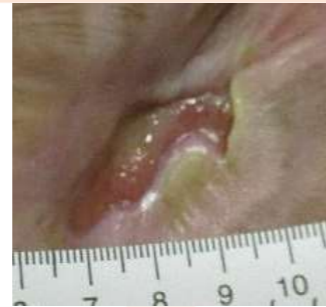[®]Hydrofera Blue; www.appulsemed.com

Results

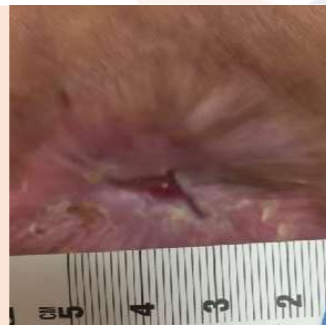
Case Study 1

Patient: 44 year old female
Medical History: Spina bifida, non-ambulatory, chronic lymphedema of right lower extremities
Wound Description: Chronic wound of the right popliteal fossa area (5 years old)
Previous Treatments: Alginate and foam

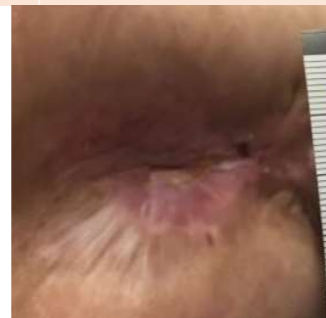Week 0:
 3.0 x 2.7 cm.
Pale pink, slough.



Week 4:
 2.0 x 1.0 cm.
Granulation tissue, epithelial tissue.



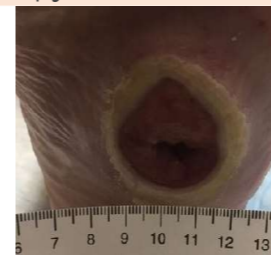Week 7:
Re-epithelialized



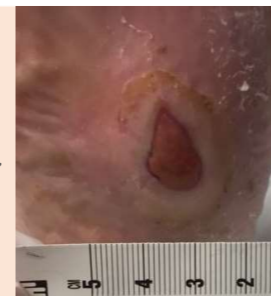Case Study 2

Patient: 62 year old female
Medical History: Morbidly obese neuropathic diabetic, improperly offloaded. Gastric bypass, Crohn's disease, immunosuppressant medications.
Wound Description: Charcot Deformity. Diabetic left foot wound (Wagner grade 3).
Previous Treatments: Hydrogen peroxide, total contact cast (TCC), Crow Walker. Hyperbaric Oxygen Therapy

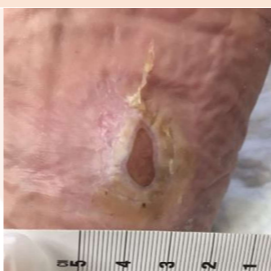Week 0:
 3.3 x 2.5 cm.
Pale pink tissue, hyperkeratotic wound edge.



Week 4:
 2.2 x 1.5 cm.
Beefy red granulation, ECM-Ag incorporating.



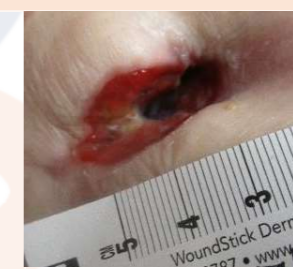Week 6:
 1.0 x 0.8 cm.
ECM-Ag incorporating Epithelial tissue.



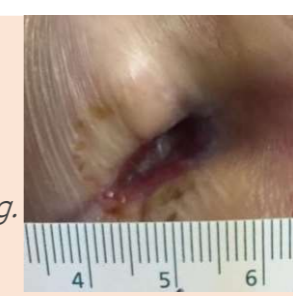
Case Study 3

Patient: 83 year old female
Medical History: Patient originally diagnosed at age 13 with a slipped femoral epiphysis and underwent multiple orthopedic surgeries that did not improve the wound. Post-operative wound infection and patient has been on oral antibiotic continuously for 8 years.
Wound Description: Open wound of right hip sinus tract (2 years).

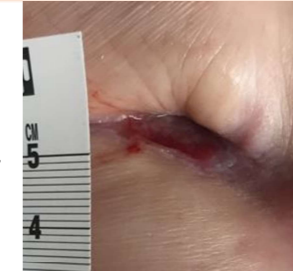Week 0:
 1.0 x 3.1 cm.
Tunneling at 4.2 cm.



Week 3:
 0.5 x 1.8 cm.
Tunneling at 2.0 cm, granulation tissue, ECM-Ag incorporating.



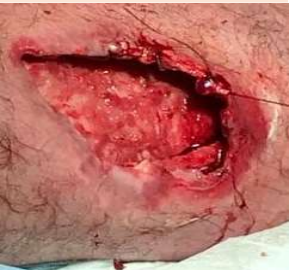Week 10:
 0.5 x 1.5 cm.
Tunneling at 4.5 cm, beefy red granulation.



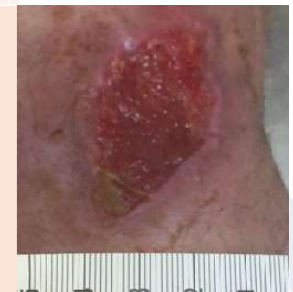Case Study 4

Patient: 65 year old male
Medical History: Involved in a severe motorcycle accident sustained multiple injuries including a deep soft tissue contusion involving the right medial thigh. Stabilized orthopedically.
Wound Description: Ischemic necrotic tissue of underlying muscle

Week 0:
 7.0 x 4.0 cm.
Muscle exposed.



Week 4:
 5.7 x 3.2 cm.
Beefy red granulation tissue.



Week 5:
 4.8 x 4.1 cm.
Beefy red granulation tissue, ECM-Ag incorporating.

