

# Successful Treatment of Calciphylaxis Ulcers with Novel Ovine Forestomach Matrix Composite with Hyaluronic Acid: A Case Series

Basil Z. Khalaf, M.D.; Medical Director, MEDiKAL VIP Medical Concierge Services, Houston, TX, USA

## INTRODUCTION

Calciphylaxis is a serious and uncommon disease in which calcium accumulates in small blood vessels of the fat and skin tissues frequently resulting in painful, non-healing skin ulcerations [1]. Ulcerations due to calciphylaxis are challenging to diagnose and treat due to their rarity and significant systemic complexity. There are limited treatment options for these challenging wounds.

Ovine forestomach matrix (OFM) is efficacious in the treatment of chronic and challenging ulcerations [2,3]. This case series highlights one provider's use of a novel composite device comprising OFM and hyaluronic acid (OFM-HA\*) to treat calciphylaxis ulcerations.

## METHOD

This is an observational, retrospective case series (n=3). Wounds were debrided ultrasonically, OFM-HA placed, hydrated with sterile saline, and secured to the peri-wound with SteriStrips®. The wounds were dressed with a contact layer, foam dressing, and gauze wrap.

## RESULTS AND DISCUSSION

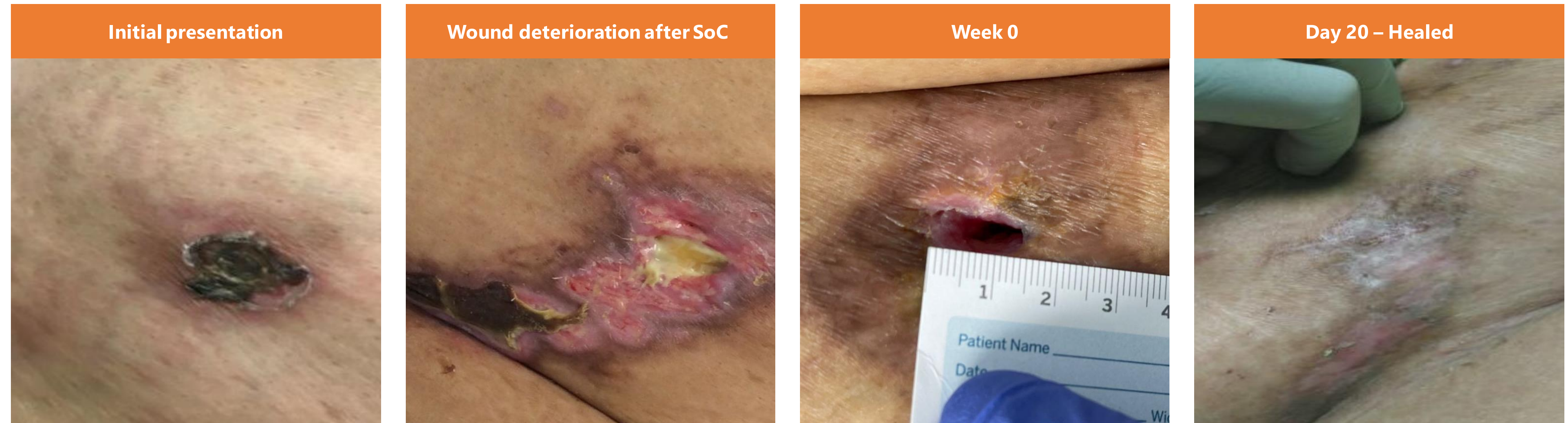All three patients included in this chart review healed uneventfully following the application of OFM-HA. Notably, n=2/3 wounds healed following a single application, and the third required only two applications. Also, all three patients noted a marked reduction in pain following initiation of OFM-HA treatment.

Novel OFM-HA device was effective in closing these challenging calciphylaxis ulcerations. A larger case series and/or prospective study may be conducted to further elucidate the potential for the treatment of challenging atypical wounds such as calciphylaxis using OFM-HA.

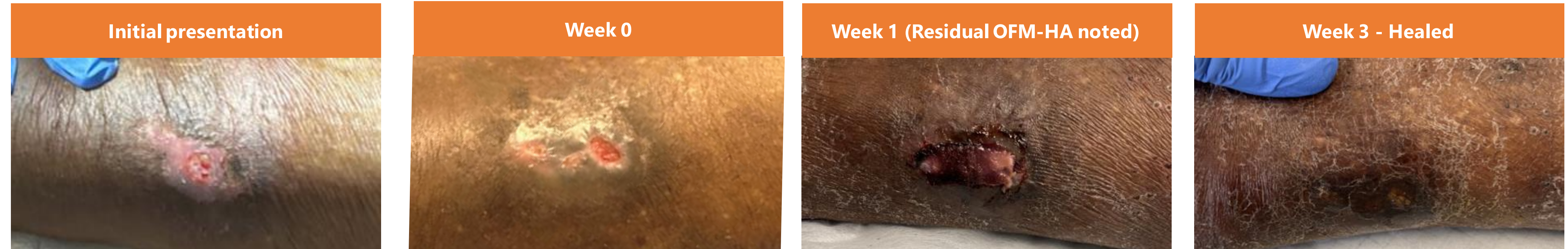
## REFERENCES AND DISCLOSURES

- \*Symphony™ Proliferative Bioscaffold, Aroa Biosurgery Limited, New Zealand. BZK is a consultant for Aroa Biosurgery Limited.
- [1] Kodumudi, V., G. M. Jeha, N. Mydlo, and A. D. Kaye. 2020. 'Management of Cutaneous Calciphylaxis', *Adv Ther*, 37: 4797-807.
- [2] Bosque, B. A., C. Frampton, A. E. Chaffin, G. A. Bohn, K. Woo, C. DeLeonardis, B. D. Lepow, M. M. Melin, T. Madu, S. G. Dowling, and B. C. H. May. 2021. 'Retrospective real-world comparative effectiveness of ovine forestomach matrix and collagen/ORC in the treatment of diabetic foot ulcers', *Int Wound J*, 2021 Aug 6: 741-53.
- [3] Raizman R, Hill R, Woo K. Prospective Multicenter Evaluation of an Advanced Extracellular Matrix for Wound Management, *Adv Skin Wound Care*, 2020, 33(8): 437-444.

### Case 1: 47-Year-old female with ESRD and DM presents with chronic calciphylaxis of the abdomen for 2 months



### Case 2: 66-Year-old male with ESRD presents with chronic calciphylaxis of the left lower leg for 8 months



### Case 3: 42-Year-old male with ESRD presents with calciphylaxis of the right medial forearm for 3 weeks

